Journal of Research in Clinical Medicine
J Res Clin Med 2026;14:35121
doi:10.34172/jrcm.35121
https://jrcm.tbzmed.ac.ir
TUOMS PRESS

Review Article

A Comprehensive Review of the Novel Treatments of Acromegaly: A Narrative Review

Halimeh Amirazad[1,2], **Amir Bahrami**[1], **Haleh Darbandi**[1], **Mostafa Najafipour**[3], **Farzad Najafipour**[1*]

[1]Endocrine Research Center, Tabriz University of Medical Sciences, Tabriz, Iran
[2]Clinical Research Development Unit, Imam Reza General Hospital, Tabriz University of Medical Sciences, Tabriz, Iran
[3]Department of Internal Medicine, Faculty of Medicine, Ardabil Azad University of Medical Sciences, Ardabil, Iran

Article info

Article History:
Received: October 6, 2024
Revised: June 3, 2025
Accepted: August 24, 2025
ePublished: September 3, 2026

Keywords:
Acromegaly, Insulin-like growth factor I, Radiotherapy, Somatostatin analogues, MicroRNAs

Abstract

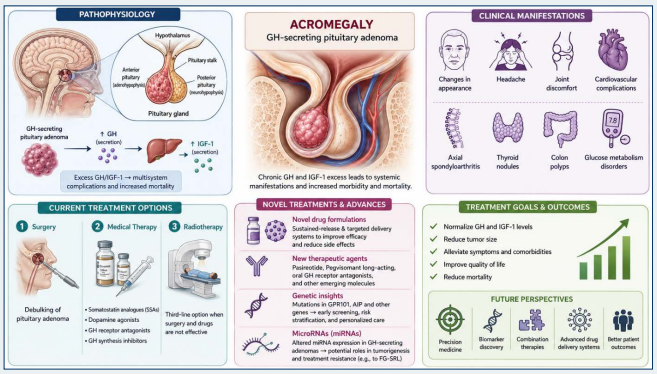

Acromegaly is a rare and heterogeneous endocrine disorder primarily caused by growth hormone-secreting pituitary adenomas. Although current therapeutic approaches, including surgery, medical therapies, and recently approved drugs, have significantly improved disease management, a considerable proportion of patients continue to exhibit persistent disease activity or treatment resistance. Therefore, the development of innovative therapeutic strategies remains essential, including new drug formulations and novel agents currently under investigation. Advances in pharmacological technologies have enhanced the efficacy and safety of acromegaly treatments. Moreover, identification of genetic alterations may facilitate early diagnosis, targeted screening, and risk assessment among affected families. Recent research has highlighted the important role of microRNAs (miRNAs) in acromegaly, particularly in regulating genes involved in pituitary tumorigenesis and resistance to treatment, especially resistance to first-generation somatostatin receptor ligands.

Introduction

Acromegaly is a rare chronic disease caused by the excessive production of growth hormone (GH) and insulin-like growth factor-1 (IGF-1), usually stemming from a pituitary adenoma.[1,2] Acromegaly leads to abnormal growth of bones and soft tissues and disrupts glucose metabolism, increasing the risk factors of cardiovascular disease and ultimately impacting mortality rates. Common clinical manifestations of acromegaly include changes in appearance, headaches, joint discomfort, cardiovascular complications, axial spondyloarthritis, and a heightened risk of thyroid nodules and colon polyps. In childhood and adolescence, GH overproduction prior to the closure of the epiphyseal plate results in gigantism, characterized by an unusually tall stature. The estimated prevalence of acromegaly ranges from 28 to 137 cases per million individuals.[3,4] Numerous previous studies have consistently shown that females are slightly more (1:1.24) affected by acromegaly than males, and the typical age of diagnosis occurs during the fifth decade of life.[5] Less than 5% of patients experience excess GH due to the secretion of growth hormone-releasing hormone (GHRH) from a neuroendocrine tumor or a hypothalamic tumor. Approximately 5% of acromegaly cases result from a genetic mutation; with the most common mutations involving G-protein receptor 101 (GPR101) or Aryl Hydrocarbon Receptor-Interacting Protein (AIP). The prevalence of genetic diversity may be notably higher in younger individuals or directly accompanied by endocrine dysfunction such as multiple endocrine neoplasia type 1 and 4, as well as Carney complex.[6]

GH circulates in the bloodstream and is partially attached to GH-binding proteins (GHBPs). The primary carrier is the high-affinity GHBP, which binds to the soluble ectodomain of the GH receptor (GHR). GH stimulates the liver, bone, fat, and muscle to produce IGF-1, and it mediates the physiological and metabolic effects of GH.

***Corresponding Author:** Farzad Najafipour, Email: farzadnajafipour@gmail.com

© 2026 The Author(s). This is an open access article distributed under the terms of the Creative Commons Attribution License (https://creativecommons.org/licenses/by/4.0/), which permits unrestricted use, distribution, and reproduction in any medium, provided the original work is properly cited.

Excessive GH production leads to the over-secretion of IGF-1, resulting in a multisystem disorder characterized by excessive physical growth, several morbidities, premature mortality, and physical deformity. GH production is also regulated by a GH-secreting receptor ligand known as ghrelin, which is primarily secreted in the gastrointestinal region, particularly in the stomach. Additionally, it is produced in the brain and spinal cord (Figure 1). There are currently three main approaches to managing acromegaly: 1) debulking surgery of the pituitary adenoma, 2) drug therapy to reduce GH overproduction or GH receptor antagonists, and 3) pituitary tumor radiotherapy. While radiotherapy is effective in the treatment of acromegaly, it is generally considered a third-line treatment after surgery and drug treatment, given the high cost and safety of medical treatment. The main complication of radiation therapy is panhypopituitarism along with potential long-term side effects. When surgical and medical interventions fail to achieve biochemical control of acromegaly, radiotherapy may be recommended.[7]

Material and Methods

A comprehensive literature search was conducted in four databases:

Embase, PubMed/MEDLINE, Scopus, and Web of Science for relevant papers published up to August 2024 that assessed the comprehensive review of the novel treatments of Acromegaly

Keywords used and search term combinations as follows:

Acromegaly [Mesh] OR "Acromegaly" [tiab] OR "Acromegaly, Insulin-like Growth Factor-1 (IGF-1)" [Mesh] OR "Acromegaly, Insulin-like Growth Factor-1 (IGF-1)" [tiab] OR " growth hormone" [tiab] OR " IGF 1, acromegaly" [Mesh] OR " IGF 1, acromegaly" [tiab] OR "Micro RNA" [tiab] OR "Micro RNA" [Mesh] OR "genetic mutation" [tiab] OR "Pituitary Surgery " [tiab] OR "Pituitary Surgery " [Mesh] AND acromegaly [Mesh] OR "somatostatine analogues "[Mesh] OR "somatostatin analogues "[Mesh] OR "somatostatin analogues "[tiab] AND (Acromegaly comprehences study OR follow-up). The literature search was not limited to publication time. Only publications published in English were included. This review article mainly included observational (cross-sectional and case-control) as well as experimental (In vitro and Preclinical) studies. Studies with insufficient information as well as letters and comments were not eligible for inclusion in the current study.

Genetic Screening

One of the most common types of pituitary adenomas is acromegaly, which often appears in family members due to Aryl Hydrocarbon Receptor Interacting Protein (AIP) gene mutations. Genetic screening and providing family members with counseling play a pivotal role in ensuring accurate and long-term management of this disorder.[6] A highly advanced next-generation quantitative Polymerase chain reaction (PCR) technique, known as droplet-based digital PCR (ddPCR), offers the advantages of heightened sensitivity, precision, and reproducibility. This portable and cost-effective device is utilized for clinical mutation detection in blood DNA, particularly for identifying GNAS gene mutations and diagnosing McCune–Albright Syndrome (MAS).[9]

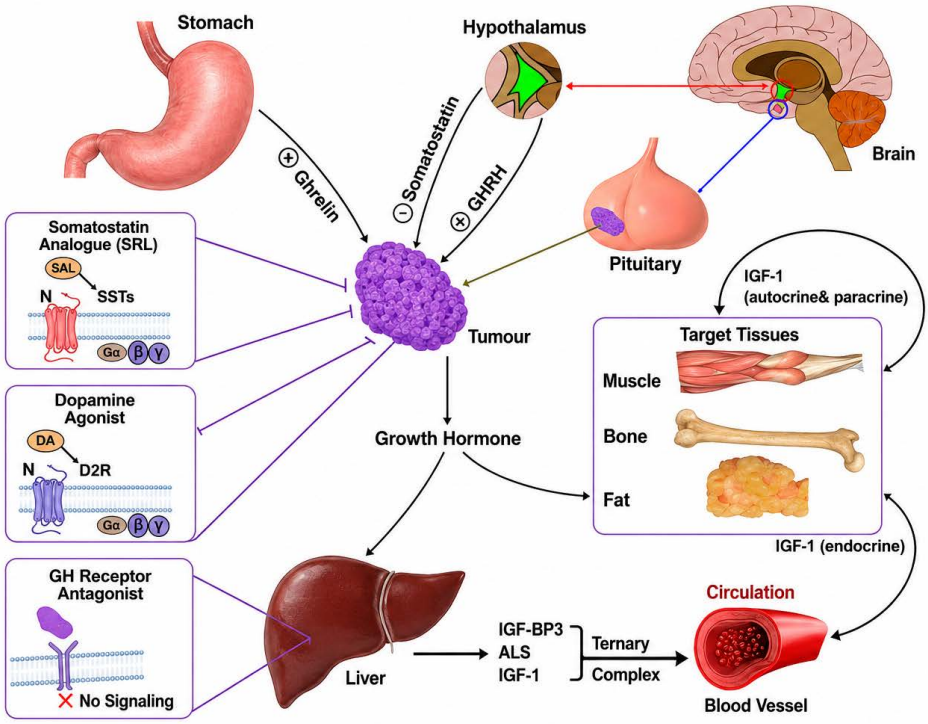

Figure 1. Regulation of GH /IGF-1 secretion indicating the sites of action of pharmacological interactions in acromegaly. [8]

Acromegaly Genetic Mutation

GH-producing pituitary adenomas are indicative of both constitutional (germline) and somatic mutations that contribute to acromegaly and gigantism. [10,11] Germline mutations involve genes such as AIP, PRKAR1A, GPR101, GNAS, MEN1, CDKN1B, SDH x, and MA. Somatic mutations, particularly in the GNAS gene, are found in approximately 40% of these tumors. Among familial isolated pituitary adenomas (FIPA), around 15–20% are related to germline mutations in the AIP gene, while mosaicism patients may harbor de novo mutations.[1,2] When the disease begins before epiphyseal fusion, rapid growth and an increase in final or tall stature can occur, especially in individuals with a genetic predisposition. Investigating the family's medical history and screening for signs of associated syndromes can be valuable in identifying potential genetic disorders. Many of these genetic tests are now being incorporated into gene panels. Next-generation gene panel sequencing includes genes such as AIP, CDKN1B, PRKAR1A, MEN1, SDHA, SDHB, SDHC, and SDHD, as recommended by reference laboratories.[12,13] The detection of genetic mutations allows for appropriate screening for comorbidities and defining the condition in family members before clinical manifestations appear.[14]

Furthermore, one of the crucial genes linked to tumor progression is the vitamin D receptor (VDR) gene, including variants like TaqI, ApaI, and BsmI, which have associations with acromegaly, osteoporotic fractures, and trabecular bone score (TBS). TBS is a valuable tool for predicting fracture risk in acromegaly patients.[5,15] In the diagnosis of acromegaly, physical and biochemical analyses, along with genetic tests and molecular methods, hold significant importance, particularly in cases associated with gene mutations as shown in Table 1.

Involvement of MicroRNA in acromegaly

Investigations have unveiled a spectrum of miRNAs implicated in somatotropinomas tumorigenesis, actively engaging in crucial signaling pathways and exhibiting correlations with tumor proliferation, invasion, and size (Table 2).[31]

Extensive research has explored the molecular mechanisms underlying diseases, with particular emphasis on RNA-related abnormalities and the crucial role of microRNAs (miRNAs). miRNAs are small non-coding RNA molecules that play a crucial role in post-transcriptional gene regulation and have been linked to the pathogenesis of various diseases, including Acromegaly. miRNAs comprise a class of short non-coding RNAs that are critically involved in the gene regulation of the pathogenesis of different diseases, including Acromegaly. [31,37]

Treatments for Acromegaly

Surgical Treatment

According to the Endocrine Society guidelines, surgery is considered the primary treatment for acromegaly. There are two main surgical methods for treating pituitary tumors in acromegaly: transsphenoidal surgery and transcranial surgery. The primary surgical approach is transsphenoidal surgery, which is considered safe and cost-effective. The objectives of surgery include normalizing GH and IGF-1 levels, preserving pituitary function, and reducing the tumor's mass effect. Recent advancements in surgical techniques and technology have provided new options and variations of established procedures. In this section of article we describe the technical progress that has emerged and been explored since transsphenoidal microsurgery became the preferred operative treatment for pituitary adenomas leading to acromegaly.[38,39]

Endoscopy

Endoscopy, which involves using a lens and light source, offers a broader field of vision compared to traditional microsurgery and eliminates the need for a direct line of sight. The advantages of endoscopy include avoiding the need for nasal speculums, mucosal dissections, and postoperative nasal tampons. Surgical instruments are introduced through the nasal cavities, and a collaborative effort between two surgeons is common. The techniques used with endoscopy closely resemble those of microsurgery. While endoscopy offers advantages, it may result in longer operation times, require larger surgical teams, exhibit higher complication rates, and involve more tissue damage compared to microsurgery. However, it remains a valuable tool, offering a wide field of view for extended approaches to certain lesions, particularly in expert centers. Overall, the choice between endoscopy and microsurgery may depend on factors like the surgeon's experience and the specific characteristics of the tumor.[40,4]

Intraoperative Magnetic Resonance Imaging

Surgeons traditionally estimate tumor resection during the procedure based on their skills and anatomical knowledge. However, since 1994, intraoperative MRI systems with excellent soft tissue contrast have been introduced for clinical use. These systems vary in magnet strength, affecting scanning time and image quality, and have different constructional setups. Typically, at least two imaging procedures are performed during surgery: before resection and at the end of resection to confirm the extent of tumor removal. Intraoperative MRI may prolong anesthesia time based on the quantity of acquired images and the cost involved in performing the procedure. The authors utilize a dataset of T2-weighted turbo spin-echo (TSE) images, both coronal and sagittal, before and after transsphenoidal surgery. These images provide exact and quick visualization of important anatomical landmarks, critical structures, cystic components, and help differentiate residual tumors from hematomas in the resection cavity. Intraoperative MRI provides valuable real-time feedback for surgeons and serves as quality control for pituitary surgery. High-field systems offer better image resolution in less time but require substantial investments. Despite advanced intraoperative MRI visualization, respectability still depends on tumor characteristics, location, and

Table 1. Genetic Mutations, Diagnosis and Type of Treatment

Gene Mutations Related to Acromegaly and Gigantism		Genetic	Diagnosis	Therapy
Germline Mutations GH Excess as an Isolated Pituitary Adenoma,[28-32,16,17]	Aryl Hydrocarbon Receptor-Interacting Protein (AIP)	AIP	Sequencing of Tumor Suppressor Genes. [1] MLPA MRI Elevated GH levels No Difference (IGF-1) & Prolactin	Radiotherapy and Reoperation if Needed, Octreotide Pasireotide
FIPA: de novo Mutations in Patients with Mosaicism[18,19]	X-Linked Acrogigantism (XLAG)	GRP101 Gene Mutation X 26.3	Genetic Testing Copy Number Variation ddPCR for GPR101	The treatment is challenging. Neurosurgery, Radiotherapy, Total Hypophysectomy. Somatostatin Analogues or Dopamine Agonists
Multiple Endocrine Neoplasia Type 1 and Type 4 (MEN1 & MEN4)[20,21]		MEN1 Gene Mutation, 11q13,	Noncancerous Tumor of Parathyroid [2] PNETs the Existence of One Typical MEN1 Tumor	Neurosurgery, MEN1 Gene Replacement, by Adenoviral Vectors, Monoclonal Antibody to the Vascular Endothelial Growth Factor (VEGF-A), that Prevents Angiogenesis
McCune–Albright Syndrome (MAS)[22,23]		GNAS gene Mutation 20 q 13.3	Physical & Biochemical Analysis, Sanger sequencing, and dd PCR from total blood	Somatostatin Pegvisomant Octreotide or lanreotide Pasireotide If simultaneous Hyperprolactinaemia arises, a Dopamine Agonist should be Prescribed. In Patients Resistant to Drug, Pituitary Surgery Should be Performed
Acromegaly in CNC [24,25]		PRKAR1A Mutation 17 q 22-24 [4] PKA Mutation, such as PRKACB.	Molecular Methods such as Sanger Sequencing. Clinical diagnosis: Characteristics include Cutaneous lesions, and Benign Tumor in the *Heart,* PPNAD, Testicular Calcification, Hypoechoic Thyroid Nodules, Breast - Ductal Adenoma,[3] PMS Blue Nevus, and Bone Tumor.	Surgery with [5] SSA. SSA would be helpful. Because of Over Activation of cAMP Signalling in these Patients.
Pituitary Adenoma Association (3Pa)—SDHx/ MAX Mutations and Phaeochromocytoma/ Paraganglioma (PPGL) [26,27]		3Pa: ([6] SDH) x Gene Mutation: SDHA, -B, -C, -D or SDHA2F. Prevents Degradation of [7] HIFα	Sequencing	Surgery with SSA
Syndromic Disease Associated with Germline Mutations and GH Excess without Visible Pituitary Tumor/ Pituitary Hyperplasia [28-30]	Neurofibromatosis Type 1 (NF1)	NF1 Gene Mutation 17q11.2.	Clinical Diagnostic Signs: [8] CNF Skin Lesions Freckling, and Brain Tumors.	SSA and Pegvisomant
	Deficiency of the Immunoglobulin Superfamily Member 1 (IGSF1)	IGSF1 Gene Mutation Xq26.1	hypothyroidism, hypoprolactinaemia macroorchidism. Adult patients (52.4%) present facial expression. but Giant stature does not happen.IGF-1 level increases	The treatment is challenging

[1] MLPA: Multiple Ligation Probe Amplification; [2] PNET: Pancreatic Neuroendocrine Tumor; [3] PMS: *Psammomatous Melanotic Schwannomas*; [4] PKA: Protein kinase A; [5] SSA: Somatostatin analogues; [6] SDH: Succinate Dehydrogenase; [7] HIF: hypoxia transcription factor; [8] CNF: Cutaneous Neurofibroma

extension.[19,20]

Neuronavigation

Neuronavigation is increasingly used in cranial and spinal neurosurgery, providing real-time guidance during minimally invasive procedures. Initially, image intensifiers were used, but these had limitations, including radiation exposure. Computerized tomography (CT) and magnetic resonance imaging (MRI) data sets are now used to enhance surgical information. Fiducials on the patient's head help align these images with the surgical field. Neuronavigation systems transfer virtual imaging data to the operative field, allowing surgeons to visualize critical structures. While generally useful for complex cases, they may not be necessary in high-volume centers. Pointer-based and advanced systems superimpose crucial structures onto the surgical field, such as carotid artery courses and tumor boundaries. However, these systems rely on preoperative data. Navigation systems have expanded the range of operable lesions via the transsphenoidal route, enabling surgery on complex cases previously considered untouchable. Neuronavigation benefits both microsurgery and endoscopic pituitary surgery, broadening the scope of operable lesions with minimal morbidity.[42,43]

Doppler probes

Doppler probes are valuable for locating the carotid artery, which can be close to tumor margins, preventing potential life-threatening arterial bleeding, a concern for transsphenoidal surgeons. Dusick et al. employed a Doppler probe to locate and safeguard the carotid artery; a technique widely used in aneurysm surgery. While specific data for acromegalic patients is lacking, this approach is generally recommended for its accessibility and enhanced safety during the procedure. Despite a lack of objective outcome data, the microvascular Doppler system has contributed to

Table 2. The miRNA profiles associated with Acromegaly

Samples	Analysis Methods	miRNA expression downregulated	miRNA expression upregulated	Description	Pathways/Proteins
miR-126 [32]	The Affymetrix Genechip miRNA 4.0 array	downregulated		Proliferation Invasion	PTTG
miR-381 [32]	The Affymetrix Genechip miRNA 4.0 array	downregulated		Proliferation Invasion	PTTG
miR-338-3p[32]	The Affymetrix Genechip miRNA 4.0 array		upregulated	proliferation Invasion	PTTG
miR-26b[33]	miRCURY™ LNA array	downregulated		Tumor size	PTEN/PI3K/AKT/mTOR
miR-128[33]	miRCURY™ LNA array		upregulated	Invasion	PTEN/PI3K/AKT/mTOR
miR-503[34]	miRCURY™ LNA array	downregulated		Differentiation, proliferation	EMT
miR-525-5p[34]	miRCURY™ LNA array		upregulated	Proliferation, invasion, migration	EMT
miR-34b [35]	miRNACHIP microarray	downregulated		Proliferation	HMGA1/2 Human [35]
miR- 548c-3p[35]	miRNACHIP microarray	downregulated		Proliferation	HMGA1/2
miR-34b [35]	miRNACHIP microarray	downregulated		Proliferation	HMGA1/2
miR-326[35]	miRNACHIP microarray	downregulated		Proliferation	HMGA1/2
miR-432[35]	miRNACHIP microarray	downregulated		Proliferation	HMGA1/2
miR-548c-3p[35]	miRNACHIP microarray	downregulated		Proliferation	HMGA1/2
miR-570 [35]	miRNACHIP microarray	downregulated		Proliferation	HMGA1/2
miR-326 [35]	miRNACHIP microarray	downregulated		Proliferation	E2F1
miR-603 [35]	miRNACHIP microarray	downregulated		Proliferation	E2F1
miR-16-1 [36]	Northern blotting	downregulated		Inverse correlation with tumor size	RARS m/p43
miR-15a [36]	Northern blotting	downregulated		Inverse correlation with tumor size	RARS m/p43
Mir503 [34]	miRCURY™ LNA array	downregulated		Differentiation proliferation	FGF2

reducing carotid artery injuries during surgery.[44,45]

Intraoperative GH Measurements

Intraoperative GH measurements have been explored to improve acromegaly surgery outcomes. The concept is straightforward: complete tumor removal should eliminate GH secretion, leading to GH levels dropping within 10 half-life periods. While some studies, like Abe and Lüdecke's, reported success with intraoperative GH measurements, others, such as Valdemarsson et al, were more critical, suggesting caution in interpreting GH half-life measurements. Otani et al. found significance in GH levels 20 minutes after tumor removal regarding remission. However, this approach faces technical and organizational challenges, including the need for rapid intraoperative GH assessment and mathematical models for prediction. As a result, it hasn't become a routine practice in surgery.[42,44,45]

Medical treatment

There are three medical treatment classes for acromegaly: Somatostatin Receptor ligands (SRLs), dopamine agonists, and GH receptor antagonists (Table 3).[43]

Somatostatin Receptor Ligands

Somatostatin receptor ligands (SRLs) are the most commonly prescribed treatment for acromegaly, with three available drugs divided into two generations. The first generation (FG-SRLs), including octreotide long-acting release (OCT-LAR) and lanreotide autogel, is considered first-line therapy. These drugs effectively control GH and IGF-I levels in about 30-40% of patients. Patients well-controlled on low-dose FG-SRLs can consider extended dosing intervals while maintaining disease control. Pasireotide (PAS), a second-generation SRL, binds to SST 1, 2, 3, and mainly 5 (Figure 2). PAS has demonstrated superior clinical outcomes were observed relative to FG-SRLs in both newly treated patients and those with suboptimal responses to FG-SRL therapy. In a real-life study, IGF-I normalization was achieved in 54% of acromegaly patients not controlled with FG-SRLs. However, PAS may lead to worsened glucose homeostasis, which is a less common side effect with FG-SRLs.[21,48]

miRNAs Associated with the response to FG-SRL

MiRNAs are critically involved in post-transcriptional regulation, primarily serving as significant suppressors of protein translation. Identifying reliable predictors for the response to FG-SRL treatment in acromegaly has been a topic of extensive discussion. Noteworthy biomarkers for predicting response include miR-181a-5p, miR-181b-5p, miR-125a-5p, miR-524-5p, and miR-886-5p, which indicate positive response, while miR-383-5p is indicative of unresponsiveness. These miRNAs can be utilized individually or integrated into prediction models to enhance clinical decision-making.[52,31] SST2 stands out as a critical predictor of response to FG-SRL, with its expression being essential for favorable outcomes in primary medical treatment. MiRNAs that modulate SST2 expression can influence the response to FG-SRL. Specifically, miR-185 has been found to regulate SST2 in vitro by binding to the 3612-3619 position of SST2 3' UTR region. Interestingly, miR-185 is upregulated in non-responders in vivo, though

Table 3. Medical treatment for Acromegaly.

Drugs	Action Mechanism	Direction	Side Effect/ Favorable Effect
FG-SRLs Octreotide LAR [46]	Somatostatin receptor ligand	Intramuscular Injection 10–30 mg every Month	Gastro-Intestinal Side Effects Reduced Quality of Life
FG- SRL Lanreotide Autogel [46]	Somatostatin receptor ligand	Subcutaneous (SC) Injection, 60–120 mg every Month	
Octreotide[47]	Somatostatin receptor ligand	Oral Capsules (Daily)	Succeeded IGF-1 and GH Normalization During the Follow up
Octreotide (CAM2029) (New formulations of FG-SRLs) [6,14,48]	Somatostatin receptor ligand	SC Injection depot 10–20 mg Monthly	Optimal biochemical IGF-1 and GH control
a prolonged release formulation (PRF) of lanreotide	somatostatin analogue	SC injection	GH and IGF-1 remained constant during the study
Second Generation SRL [49]	Pasireotide (PAS)	SC Injection	Optimal Disease Control and Tumor Shrinkage in Comparison with FG-SRLs
Combination Therapy [50]	PAS-LAR	40–60 mg Every Month	Good Biochemical Control Disappearance of Headaches Tumor Shrinkage

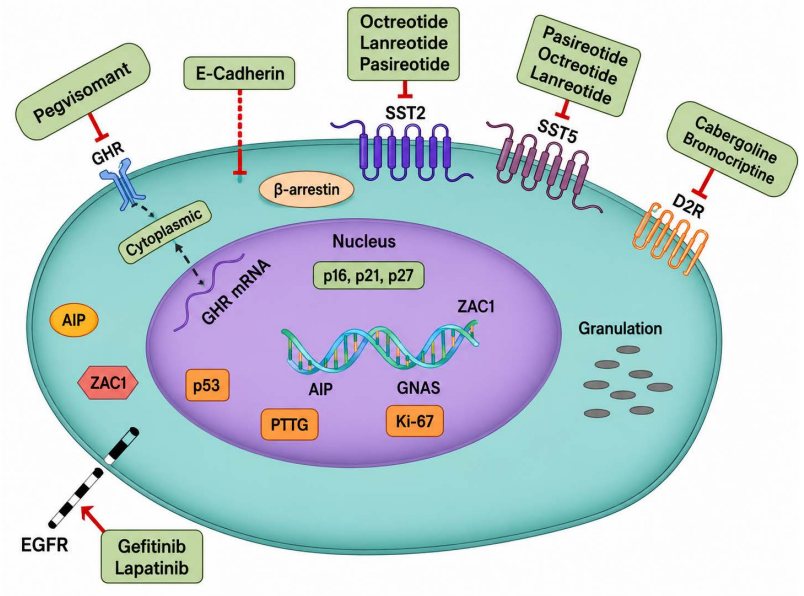

Figure 2. Cell surface receptors as molecular targets and drugs action mechanism Redrawn from Labadzhyan et al. [51]

no direct correlation with SST2 was identified in vivo.[53,54] The response of tumors to FG-SRL varies based on the level of miR-34a. However, complementary data by Bogner et al. suggest that AIP regulates miR-34a expression. This miRNA targets the alpha subunit of the G inhibitory protein (Gαi2) from SST2, leading to a diminished response to FG-SRL. Subsequent investigations are necessary to establish the utility of miRNAs as a valuable instrument in the pharmacological treatment of acromegaly.[19,31]

Dopamine Agonists

Dopamine agonists, for instance cabergoline, are restricted effectiveness in acromegaly and are typically used as supplementary therapy for cases with mildly elevated IGF-I levels (< 2.5 × threshold of the normal range). Long-term disease control is achieved in only 18% of patients when used as monotherapy.[44]

GH Receptor Antagonists

Pegvisomant (PEGV) is a GH receptor antagonist that prevents the action of GH in the body. It is often used when other treatments are not effective in controlling GH and IGF-1 levels.[2] Pegvisomant, a selective GH receptor antagonist, is commonly managed as a second-line treatment option. Clinical trials have shown it can achieve biochemical control rates of 90% or higher, while real-life usage indicates approximately 70% control rates. [43,49]

Combination Therapies

Monotherapy alone often falls short of achieving comprehensive biochemical control in a significant portion of clinical patients. Consequently, the utilization of combined drug therapies becomes imperative to enhance clinical outcomes. In instances where patients exhibit only partial responses, the advantage of combined medical treatments becomes evident in their ability to mitigate the side effects associated with higher individual medication dosages. This is achieved by reducing the frequency of injections and/or the total drug dosage required.[55] The combinations employed in the treatment of acromegaly

encompass FG-SRLs + Cabergoline, which enables disease control was attained in about 23% of patients, and FG-SRLs +PEGV and PEGV+ cabergoline, yielding disease control rates akin to PEGV monotherapy while bestowing further clinical effects in terms of tumor action and allowing for reduced PEGV doses.[43,49] In some cases, patients may not respond adequately to first-generation SRLs, leading to the consideration of second-generation SRL(Figure 3).

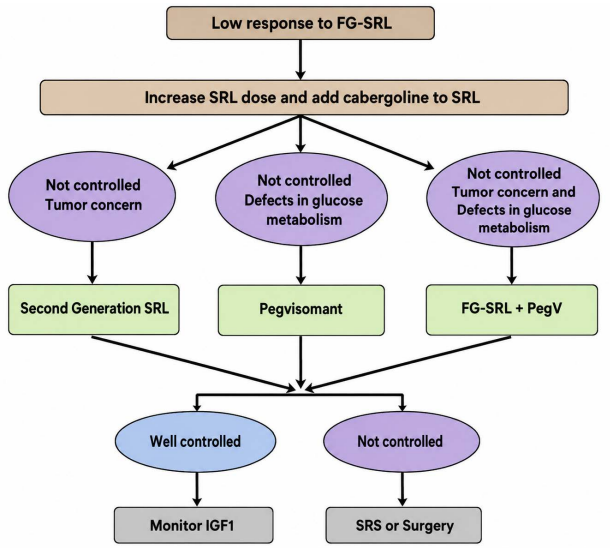

Figure 3. A proposed algorithm for the treatment of acromegaly in patients who show low response to FG-SRLs.[56]

Other drug therapies

Beyond the previously discussed three categories of drugs employed in acromegaly treatment, there exist other medical therapies reserved for specific circumstances. Among these, oral estrogens and selective estrogen receptor modulators (SERMs) demonstrate the capacity to reduce IGF-I levels by controlling GH responsiveness. They achieve this through induction of SOCS2 expression, which in turn negatively regulates the GHR–JAK2–STAT5 signaling cascade. This phenomenon, often referred to as the "first-pass effect," may be observed in acromegaly patients when these medications are utilized either alone or in conjunction with an SRL or cabergoline. Temozolomide, on the other hand, is an alkylating agent known for inducing DNA damage, ultimately leading to the demise of tumor cells.[49,57] It serves as a form of chemotherapy reserved for aggressive pituitary tumors and pituitary carcinomas that do not respond to the aforementioned standard therapeutic approaches.[43,57]

Radiotherapy

Radiation therapy (RT) is typically classified as a third-line treatment option, primarily employed as an adjunct treatment for patients dealing with aggressive tumors that have not responded to surgical and medical interventions.[58,59]

Conventional (2D) Radiation Therapy

Conventional radiotherapy (CRT) is the most frequent form of radiotherapy utilized. It often needs the use of posterior and anterior rays.[56] CRT is performed at a 40-45Gy dose supplied at a minimum of 20 courses. Although CRT provides durable control of tumor size and finally leads to optimal biochemical control of GH/IGF1., it has side effects such as hypopituitarism in 30–80% of patients, cerebrovascular deficit, and cranial nerve dysfunction. In recent times, developments in imaging and computer related designs have made progress in modern radio therapeutic approaches to enhance local control rates and decrease radiation-induced problems.[60,61]

Gamma knife Radiosurgery

Gamma knife radiosurgery (GKS) is an effective treatment option for recurrent condition in acromegaly patients. This approach has minimal side effects, ensures endocrine control, and increases the remission rate. In a study by Anne Balossier et al, the results indicated that IGF-1 levels were normal at 3 years (65%) and 4 years (72.4%), with 52.4% of patients achieving complete biochemical remission, a rate that remained consistent throughout the follow-up period (62.5 months).[61,17] Multiple studies support the effectiveness and safety of Gamma Knife surgery for GH-secreting pituitary adenomas.[62,63]

Modern Stereotactic Radiation Therapy

Stereotactic techniques include fractionated stereotactic radiotherapy (FSRT) and stereotactic radiosurgery (SRS). SRS is typically reserved for tumors smaller than 3cm in size and situated at a distance of more than 3mm from critical optic structures. On the other hand, FSRT is often employed in the treatment of large pituitary tumors that have encroached upon or are directly involving the optic nerve.[58] These techniques deliver precise, high doses of radiation to specific regions of the tumor, minimizing irradiation to surrounding brain tissue and reducing the risk of subsequent damage. Stereotactic radiosurgery can be performed using protons or photons, and it is available through technologies like the Gamma Knife (GK), CyberKnife (CK), and medical linear accelerator (LINAC). GK and CK are surgical approaches used in the treatment of acromegaly patients. LINAC operates in three dimensions and employs X-rays generated from atomic and electron collisions with a metal target. Therapy is administered through various arcs or beams shaped with multileaf collimation.[64,65] Several comparative studies have explored the efficacy of different treatment modalities SRS, CRT, and FSRT in managing acromegaly. Stereotactic radiosurgery has now emerged as a pivotal therapeutic approach and demonstrates both effectiveness and safety for patients dealing with acromegaly, especially those who have undergone non-curative surgery or insufficient response to treatment or tolerated pharmaceutical interventions.[58]

Novel therapy

The current clinical management of acromegaly falls short of being considered ideal. This is because not all patients attain the desired level of biochemical control, and adverse events can be particularly severe in certain individuals,

resulting in intolerance and restricted use of available treatments. Furthermore, with the exception of dopamine agonists (DA), all commonly used medications necessitate regular injections, which can potentially diminish the quality of life for patients. There has been a surge of interest in exploring novel therapies through preclinical and clinical trials. [43] These innovations include not only entirely new therapeutic agents but also novel SRLs featuring different modes of administration or innovative combinations of currently available drugs (Table 4).

New Combination of Drugs Already Approved

Pasireotide and Pegvisomant

PAS and pegvisomant (PEGV) are two highly effective drugs used in acromegaly treatment, but their combined use has been relatively underexplored. This combination offers potential benefits such as reducing the PEGV dosage, leading to cost savings, minimizing glucose-related issues correlated with PAS alone, and achieving biochemical control in cases insensitive to standard medical therapies. The PAPE study is the sole published trial investigating the efficacy and safety of PAS either alone or as part of combination therapy with PEGV. Hyperglycemia was the most frequently reported adverse event throughout the study, with a frequency of diabetes mellitus (DM) increasing from 68.9% at 6 months to 77% at one year. A recent study demonstrated the effectiveness of combining PAS and PEGV in controlling acromegaly in six patient's resistant to conventional treatments. These patients had undergone pituitary neurosurgery and were treated with various medications, including PAS and PEGV. Despite initial challenges, biochemical control of acromegaly was achieved in all six patients under combination therapy, and adverse effects on glycemic control were managed through insulin therapy adjustments and dietary changes. The results emphasize the concept of personalized treatment and the potential for combining medications to control the disease.[43]

New class of drugs

Novel therapeutic agents may improve the management of acromegaly, especially in cases where traditional therapies may not be fully effective.

Octreotide capsule

In preclinical studies, use of an octreotide capsule with TPE (Technology of Peptide Encapsulation) showed similar pharmacokinetic profiles to subcutaneous (SC) injection, effectively suppressing GH levels. The capsule demonstrated intestinal permeability in rat models, with the best absorption for smaller dextrans coupled with TPE. A phase 1 study in healthy subjects revealed dose-dependent oral administration and comparable effects to injection, with delayed onset but sustained suppression of GH levels. Food intake and proton pump inhibitors affected capsule absorption. A phase 3 study in acromegaly patients showed sustained biochemical control with oral octreotide, especially in those with good baseline control on injectable drugs. Clinical symptoms also improved, and adverse effects were mostly mild to moderate gastrointestinal, neurological, and musculoskeletal symptoms.[43]

Table 4. Novel Drugs in the Treatment of Acromegaly

Drugs	Action Mechanism	Clinical Trial Phase	Direction	Side Effect/ Favorable Effect
PAS- PEGV[50,43]	Somatostatin receptor ligand + GHR antagonist	Phase 4	Pasireotide 60 mg IM Monthly + Pegvisomant 21-78 mg SC weekly	Good Biochemical Control/ Hyperglycemia, new-onset diabetes, gastrointestinal, headache, arthralgia myalgia, fatigue
ATL1103[43]	Antisense oligonucleotide inhibitor of GHR	Phase 2 completed	200 mg SC weekly	headache, fatigue,gastrointestinal raised liver enzymes
ISIS 766720 NCT03548415[43,66]	Antisense oligonucleotide inhibitor of GHR	Phase 2 completed	Single SC doses 28–28 days (dosage not available)	Not Available
Mycapssa (Octreotide)[6,14,48]	Somatostatin receptor ligand (SSRL)	Phase 3 completed (recently FDA approved	Oral 20–40 mig bid	Trials are still ongoing, results are not available
Lanreotide PRF[6,14,48]	Somatostatin receptor ligand (SSTR2 & SSTR5)	Phase 2 completed	SC Injection 180–360 mg every 3 Months	Not Available
Debio 4126 (Octreotide)	somatostatin analogue therapy (SSA3)	Phase 1 (ongoing)	Intramuscular Injection once every 4 weeks to once every 12 weeks	Not Available
Paltusotine NCT03789656 NCT03792555 NCT04261712[22,28]	Somatostatin receptor 2 biased agonist	Phase 3 (ongoing)	Oral 5– 60 mg (daily)	Adverse effects were minor and similar to other SRLs
Somatropin [3,12,11,26,10,25,34]	binds to the human growth hormone receptor	Phase 2 completed	SC Injection	Trials are still ongoing, results are not available
ONO-5788 (SST2) [14,48]	(SSRL)	Phase 1 (ongoing)	Oral	
ONO-ST-468[14]	SSRL	Phase 1 (ongoing)	Oral	

Somatostatin receptor 2 biased agonist

Somatostatin receptor ligands (SRLs) represent a significant advancement in the medical treatment of acromegaly.[19-21] Paltusotine, formerly known as CRN00808, is an emerging treatment for a medical condition. It is an oral, selective, nonpeptide agonist that targets somatostatin receptor 2 (SST2) (Figure 2). Biased agonism refers to its ability to activate a specific subset of a receptor's signaling pathways, distinct from other ligands. A phase 1 clinical trial in 2018 involving 99 healthy volunteers evaluated its safety, pharmacokinetics, pharmacodynamics, and potential interactions with midazolam. The drug was well absorbed and exhibited a half-life of 42–50 hours, supporting once-daily dosing. Stable levels were achieved in 3-5 days. Taking the drug with food significantly reduced systemic exposure. GH and IGF-I secretion decreased in a dose-dependent manner after oral administration, with the most significant suppression observed at a 10 mg dose. Co-administration with midazolam showed no significant pharmacokinetic changes, suggesting a low risk of interaction. Adverse events were generally mild and consistent with known side effects of similar treatments. Paltusotine is currently being assessed in a phase 3 clinical trial involving acromegaly patients who were previously controlled with first-generation SRLs, focusing on both safety and efficacy**.** Results from this trial are expected in 2023 (ClinicalTrials.gov Identifier: NCT04837040). The development of various formulations has expanded innovative possibilities for tailoring treatment to individual patient conditions.[16,40,67]

Antisense Oligonucleotide

ATL1103

A novel type of medication known as antisense oligonucleotides is gaining attention. These are synthetic single-stranded sequences of nucleotides designed to target specific mRNA molecules, ultimately halting gene transcription and protein synthesis. ATL1103 blocks the expression of GHR, consequently reducing IGF-I levels. This drug features a unique structure composed of a 20-nucleotide DNA core featuring a phosphorothioate backbone and 2′-O-methoxyethyl modifications at its ends, ATL1103 hybridizes with GHR mRNA and triggers RNase H–mediated degradation of the complex structure, leading to the degradation of GHR mRNA and the prevention of gene transcription. Additional research using higher doses and extended treatment durations are necessary to explore the full potential of this innovative approach.[43]

ISIS 766720

Two clinical trials are currently in the recruitment phase, both involving an antisense inhibitor of GHR. The first trial aimed at evaluating the safety, tolerability, and effectiveness of ISIS 766720 (IONIS-GHRLRx). The drug is administered once every 28 days over a 16-week period in 60 patients with acromegaly receiving first-generation somatostatin receptor ligands (FG-SRLs). Eligible participants are required to be on stable maximal or maximally tolerated FG-SRL doses and to have serum IGF-I levels between 1.3 and 5 times the age- and sex-adjusted upper limit of normal at screening (ClinicalTrials.gov identifier: NCT03548415). A separate open-label extension study includes the same 60 participants, who continue treatment at the previously assigned dose for an additional 53 weeks. (ClinicalTrials.gov Identifier: NCT03967249). Some biomarkers, such as SST2 expression, have been described in the literature, indicating a higher likelihood of disease control in patients with high expression of this biomarker. Additional biomarkers include tumor intensity on MRI, baseline IGF-I concentrations, patient age, and body weight. Although additional molecular and histopathological markers have been proposed, their clinical utility remains limited due to the lack of standardized assessment methods and validated reference ranges.[43,66] Despite the identification of several biomarkers associated with treatment response in acromegaly, further refinement, validation, and standardization are needed before they can be routinely incorporated into clinical practice., particularly in conducting larger studies with rigorous methods to analyze these biomarkers for practical clinical application.[31] There are some tests to predict the response to PAS in patients with acromegaly:

Imaging Markers to Predict the Response to Pasireotide

The T2-weighted MRI signal is a valuable indicator of the expected response of somatotropinomas to both first-generation somatostatin receptor ligands (FG-SRLs) and PAS. Specifically, a dense granular (DG) somatotropinoma pattern typically exhibits a hypointense T2-weighted signal and is responsive to SRLs, whereas a sparse granulation pattern does not respond as effectively. Moreover, MRI can be equally useful in predicting the response to FG-SRLs following unsuccessful surgery and should consistently be considered as a biomarker of treatment response. Patients with a T2 hypointense signal tend to experience a reduction in IGF-1 levels six months after starting FG-SRL treatment. On the other hand, patients with a hyperintense T2 signal and those exhibiting high expression of SST5 and low expression of SST2, along with a sparse granulation (SG) immunohistochemical pattern, have been shown to benefit from PAS. Conversely, these patients do not tend to respond as favorably to first-generation SRLs. Therefore, assessing the T2-weighted signal is highly recommended as it provides valuable insights into patients' treatment responses.[16] In conclusion, the texture analysis of T2-weighted images has seen recent advancements and can accurately categorize responses to FG-SRLs in over 80% of patients. Consequently, further research in this area is warranted to continue improving our understanding and management of acromegaly. [68]

Functional Tests to Predict the Response to Pasireotide

Functional testing is a valuable tool for identifying pathological hormonal conditions and assessing individual responses to specific drugs like PAS. One such test is the acute octreotide test (AOT), which is used to assess the therapeutic response to long-acting somatostatin receptor ligands (SRLs). The AOT is highly effective in predicting

the long-term outcomes of SRL therapy in patients with acromegaly. Importantly, it can accurately identify individuals who do not respond well to first-generation SRLs, thereby allowing for the optimization of the standard sequential drug treatment approach and the introduction of alternative medications. This test is not only cost-efficient but also practical in clinical settings and can provide valuable insights after surgical interventions. [68]

Personalized Medicine in Acromegaly Treatment

The management of acromegaly requires a personalized and multimodal approach, combining surgery, medical therapies, radiotherapy, and, in specific cases, emerging novel drugs. The treatment is intended to restore normal levels of GH and IGF-1, control tumor growth, and alleviate clinical symptoms. Applying precision medicine to acromegaly is promising due to the variety of available treatments and emerging biomarkers that can predict drug response. This is particularly relevant for first-generation somatostatin receptor ligands (fg-SRLs), which remain the primary therapy despite 20–25% of patients being resistant. Personalized treatment could improve disease control by identifying the most effective therapy sooner, reduce GH burden, and lower costs by avoiding ineffective medications. However, widespread adoption is limited by small, heterogeneous studies and inconsistent methods for analyzing key biomarkers—especially sst2 expression, which varies depending on the techniques and criteria used in different studies. Standardizing these methods is essential for clinical use.

Despite these challenges, current data support a more personalized treatment algorithm. Surgery remains the first-line treatment, offering both therapeutic and diagnostic benefits by providing tumor tissue for biomarker analysis. In cases of surgical failure, biomarkers like sst2, sst5, AIP, and DR2, along with biochemical and tumor characteristics, can guide medical treatment. Two patient cases highlight the importance of biomarker-guided therapy. The first, with high sst2 and AIP expression, responded well to octreotide. The second, with low sst2 and AIP but high sst5 expression, showed resistance. Knowledge of these profiles beforehand could have enabled a better treatment choice, such as using PAS instead of octreotide.

In brief, an individualized treatment plan for acromegaly should consider tumor size, invasiveness, hormonal activity, comorbidities, and patient preferences. Surgical resection remains central, complemented by targeted medical therapies, radiotherapy, and innovative drug options. Biomarkers and functional tests are valuable tools for optimizing therapeutic choices and improving long-term disease management.

Discussion

Advancements in drug formulations have substantially enhanced the effectiveness of treatment for acromegaly, particularly with the development of extended-release formulations and novel drugs. The ongoing progress in somatostatin receptor ligands (SRLs) is expanding treatment options, offering promising avenues for potential new therapies in future clinical practice.

The utilization of modern technology in transsphenoidal microsurgery has resulted in modest improvements in outcomes while expanding the range of treatable conditions and enhancing patient safety during procedures. Despite the advancements in novel biochemical tests and imaging techniques, substantial gaps still exist in clarifying the diagnosis and managing complications associated with this condition.[41] It should be emphasized that treatment decisions are guided by the individual response of each patient and the specific characteristics of their circumstances.

Conclusion

Acromegaly represents a life-threatening condition that significantly impacts an individual's quality of life when effective biochemical control remains elusive. Although existing medical treatments are generally effective and relatively safe, a notable proportion of patients still struggle to achieve disease management. Consequently, the exploration of innovative formulations or the combination of approved medications with emerging compounds in clinical development promises to usher in a new era for these challenging cases. Progress in our scientific understanding of pituitary tumor characteristics, including growth patterns, gene mutations, and immunohistochemically profiles, as well as considerations of patient-specific factors such as comorbidities and GH/IGF-I levels, will play a pivotal role in identifying disease response biomarkers. This, in turn, will enable a personalized approach to treatment rather than relying on a one-size-fits-all algorithmic strategy.

Acknowledgements

The authors would like to acknowledge the support of the Endocrine Research Center, Tabriz University of Medical Sciences, for this project. They also extend their appreciation to Imam Reza Hospital, Tabriz, Iran, for their assistance.

Authors' Contribution

Conceptualization: Farzad Najafipour
Investigation: Halimeh Amirazad, Farzad Najafipour
Supervision: Amir Bahrami, Farzad Najafipour
Data Curation: Haleh Darbandi
Writing–Original Draft: Halimeh Amirazad
Writing–Review & Editing: Haleh Darbandi, Mostafa Najafipour

Competing Interests

The authors report no competing interest in this work.

Consent for Publication

Not applicable.

Data Availability Statement

Not applicable.

Ethical Approval

Ethical committee approval was received from the Ethics Committee of Tabriz University of Medical Sciences on 9 Sep 2024 (approval No: IR.TBZMED.REC. 1403.464).

Funding
Authors did not receive any funding to carry out this research.

References

1. Vilar L, Vilar CF, Lyra R, Lyra R, Naves LA. Acromegaly: clinical features at diagnosis. Pituitary 2017;20(1):22-32. doi:10.1007/s11102-016-0772-8
2. Cordido F, García-Arnés JA, Marazuela Aspiroz M, Torres Vela E. Practical guidelines for diagnosis and treatment of acromegaly. Endocrinol Nutr (Engl Ed) 2013;60(8):457.e1-15. doi:10.1016/j.endoen.2013.10.012
3. Lavrentaki A, Paluzzi A, Wass JA, Karavitaki N. Epidemiology of acromegaly: review of population studies. Pituitary 2017;20(1):4-9. doi:10.1007/s11102-016-0754-x
4. Jafari MM, Ayromlou H, Amirazad H, Aliasgharzadeh A. Thyroid autoimmunity in patients with multiple sclerosis before and after treatment. J Res Clin Med 2025;13(1):34511. doi:10.34172/jrcm.025.34511
5. Bogusławska A, Korbonits M. Genetics of acromegaly and gigantism. J Clin Med 2021;10(7):1377. doi:10.3390/jcm10071377
6. Gadelha MR, Kasuki L, Korbonits M. The genetic background of acromegaly. Pituitary 2017;20(1):10-21. doi:10.1007/s11102-017-0789-7
7. Hannon MJ, Barkan AL, Drake WM. The role of radiotherapy in acromegaly. Neuroendocrinology 2016;103(1):42-9. doi:10.1159/000435776
8. Espinosa E, Ramirez C, Mercado M. The multimodal treatment of acromegaly: current status and future perspectives. Endocr Metab Immune Disord Drug Targets 2014;14(3):169-81. doi:10.2174/1871530314666140609110308
9. Martins AF, Santos M, Rosário F. Caloric restriction as a possible pitfall for persistent acromegaly follow-up - case report. BMC Endocr Disord 2023;23(1):68. doi:10.1186/s12902-023-01319-0
10. Ein-Mozaffari B, Aliasgharzadeh A, Najafipour F, Moslemi A, Niafar M, Sadra V, et al. Comparison of urinary prolactin and serum/urine prolactin ratio in hyperprolactinemic and macroprolactinemic patients. BMC Endocr Disord 2025;25(1):229. doi:10.1186/s12902-025-02052-6
11. Najafipour F, Hedayati N, Hedayati N, Farhoudi M. Association of the severity and pattern of pituitary adenoma-related headache with the size and type of adenoma. J Prev Epidemiol 2024;9(2): e35213. doi:10.34172/jpe.2023.35213
12. Plöckinger U, Hoffmann U, Geese M, Lupp A, Buchfelder M, Flitsch J, et al. DG3173 (somatoprim), a unique somatostatin receptor subtypes 2-, 4- and 5-selective analogue, effectively reduces GH secretion in human GH-secreting pituitary adenomas even in octreotide non-responsive tumours. Eur J Endocrinol 2012;166(2):223-34. doi:10.1530/eje-11-0737
13. Komagata T, Tanaka H, Ishida A, Sawada T, Neki S, Iida H, et al. MON-464 non-clinical profiling of ONO-5788, a novel oral small molecule somatostatin receptor type-2 (SST2) agonist, to support studies in humans. J Endocr Soc 2019;3(Suppl 1): MON-464. doi:10.1210/js.2019-MON-464
14. Tanaka H, Komagata T, Nishio T, Ishida A, Okada H, Katsumata S, et al. MON-477 octreotide and ONO-ST-468, a novel and potent somatostatin receptor type-2 (SST2) agonist, suppress GH hypersecretion in the monkey. J Endocr Soc 2019;3(Suppl 1): MON-477. doi:10.1210/js.2019-MON-477
15. Jawiarczyk-Przybyłowska A, Halupczok-Żyła J, Kolačkov K, Gojny Ł, Zembska A, Bolanowski M. Association of vitamin D receptor polymorphisms with activity of acromegaly, vitamin D status and risk of osteoporotic fractures in acromegaly patients. Front Endocrinol (Lausanne) 2019;10:643. doi:10.3389/fendo.2019.00643
16. Kocak B, Durmaz ES, Kadioglu P, Polat Korkmaz O, Comunoglu N, Tanriover N, et al. Predicting response to somatostatin analogues in acromegaly: machine learning-based high-dimensional quantitative texture analysis on T2-weighted MRI. Eur Radiol 2019;29(6):2731-9. doi:10.1007/s00330-018-5876-2
17. Škorić Polovina T, Režić T, Kraljević I, Heinrich Z, Solak M, Dušek T, et al. Gamma-knife radiosurgery in acromegaly: the results from the Croatian acromegaly registry. Br J Neurosurg 2024;38(4):833-7. doi:10.1080/02688697.2021.1976393
18. Rostomyan L, Daly AF, Petrossians P, Nachev E, Lila AR, Lecoq AL, et al. Clinical and genetic characterization of pituitary gigantism: an international collaborative study in 208 patients. Endocr Relat Cancer 2015;22(5):745-57. doi:10.1530/erc-15-0320
19. Bogner EM, Daly AF, Gulde S, Karhu A, Irmler M, Beckers J, et al. miR-34a is upregulated in AIP-mutated somatotropinomas and promotes octreotide resistance. Int J Cancer 2020;147(12):3523-38. doi:10.1002/ijc.33268
20. Marques P, Caimari F, Hernández-Ramírez LC, Collier D, Iacovazzo D, Ronaldson A, et al. Significant benefits of AIP testing and clinical screening in familial isolated and young-onset pituitary tumors. J Clin Endocrinol Metab 2020;105(6): e2247-60. doi:10.1210/clinem/dgaa040
21. Isailovic T, Todorovic V, Milicevic I, Petakov M, Macut D, Ognjanovic S, et al. Ectopic co-secretion of growth hormone and growth hormone-releasing hormone from a neuroendocrine lung tumor in a patient with MEN1 syndrome. Endocrine Abstracts 2014;35: P313. doi:10.1530/endoabs.35.P313
22. Wong SC, Zacharin M. Long-term health outcomes of adults with McCune-Albright syndrome. Clin Endocrinol (Oxf) 2017;87(5):627-34. doi:10.1111/cen.13419
23. Salenave S, Boyce AM, Collins MT, Chanson P. Acromegaly and McCune-Albright syndrome. J Clin Endocrinol Metab 2014;99(6):1955-69. doi:10.1210/jc.2013-3826
24. Cuny T, Mac TT, Romanet P, Dufour H, Morange I, Albarel F, et al. Acromegaly in Carney complex. Pituitary 2019;22(5):456-66. doi:10.1007/s11102-019-00974-8
25. Bertherat J, Horvath A, Groussin L, Grabar S, Boikos S, Cazabat L, et al. Mutations in regulatory subunit type 1A of cyclic adenosine 5′-monophosphate-dependent protein kinase (PRKAR1A): phenotype analysis in 353 patients and 80 different genotypes. J Clin Endocrinol Metab 2009;94(6):2085-91. doi:10.1210/jc.2008-2333
26. Xekouki P, Brennand A, Whitelaw B, Pacak K, Stratakis CA. The 3PAs: an update on the association of pheochromocytomas, paragangliomas, and pituitary tumors. Horm Metab Res 2019;51(7):419-36. doi:10.1055/a-0661-0341
27. Mougel G, Lagarde A, Albarel F, Essamet W, Luigi P, Mouly C, et al. Germinal defects of SDHx genes in patients with isolated pituitary adenoma. Eur J Endocrinol 2020;183(4):369-79. doi:10.1530/eje-20-0054
28. Hannah-Shmouni F, Stratakis CA. Growth hormone excess in neurofibromatosis 1. Genet Med 2019;21(5):1254-5. doi:10.1038/s41436-018-0312-1
29. Faucz FR, Horvath AD, Azevedo MF, Levy I, Bak B, Wang Y, et al. Is IGSF1 involved in human pituitary tumor formation? Endocr Relat Cancer 2015;22(1):47-54. doi:10.1530/erc-14-0465
30. Regazzo D, Gardiman MP, Theodoropoulou M, Scaroni C, Occhi G, Ceccato F. Silent gonadotroph pituitary neuroendocrine tumor in a patient with tuberous sclerosis complex: evaluation of a possible molecular link. Endocrinol Diabetes Metab Case Rep 2018;2018:18-0086. doi:10.1530/edm-18-0086
31. Henriques DG, Lamback EB, Dezonne RS, Kasuki L, Gadelha MR. MicroRNA in acromegaly: involvement in the pathogenesis and in the response to first-generation somatostatin receptor ligands. Int J Mol Sci 2022;23(15):8653. doi:10.3390/ijms23158653
32. Lee YJ, Cho JM, Moon JH, Ku CR, Kim J, Kim SH, et al. Increased miR-338-3p expression correlates with invasiveness of GH-

producing pituitary adenomas. Endocrine 2017;58(1):184-9. doi:10.1007/s12020-017-1390-6
33. Palumbo T, Faucz FR, Azevedo M, Xekouki P, Iliopoulos D, Stratakis CA. Functional screen analysis reveals miR-26b and miR-128 as central regulators of pituitary somatomammotrophic tumor growth through activation of the PTEN-AKT pathway. Oncogene 2013;32(13):1651-9. doi:10.1038/onc.2012.190
34. Mao ZG, He DS, Zhou J, Yao B, Xiao WW, Chen CH, et al. Differential expression of microRNAs in GH-secreting pituitary adenomas. Diagn Pathol 2010;5:79. doi:10.1186/1746-1596-5-79
35. D'Angelo D, Palmieri D, Mussnich P, Roche M, Wierinckx A, Raverot G, et al. Altered microRNA expression profile in human pituitary GH adenomas: down-regulation of miRNA targeting HMGA1, HMGA2, and E2F1. J Clin Endocrinol Metab 2012;97(7): E1128-38. doi:10.1210/jc.2011-3482
36. Bottoni A, Piccin D, Tagliati F, Luchin A, Zatelli MC, degli Uberti EC. miR-15a and miR-16-1 down-regulation in pituitary adenomas. J Cell Physiol 2005;204(1):280-5. doi:10.1002/jcp.20282
37. Farashi E, Halimi M, Rasihashemi SZ. Large bilateral non-functional adrenal myelolipomas: a rare case report. J Res Clin Med 2024;12(1):19. doi:10.34172/jrcm.32267
38. Brunetti A, Antonini S, Saladino A, Lavezzi E, Zampetti B, Cozzi R. Clinical management of acromegaly: therapeutic frontiers and new perspectives for somatostatin receptor ligands (SRLs). Medicina (Kaunas) 2022;58(6):794. doi:10.3390/medicina58060794
39. Farnam A, Jahan A, Shirzadi M, Farhang S. Word and nonword repetition in patients with Schizophrenia. J Anal Res Clin Med 2015;3(3):178-82. doi:10.15171/jarcm.2015.028
40. Zhao J, Fu H, Yu J, Hong W, Tian X, Qi J, et al. Prospect of acromegaly therapy: molecular mechanism of clinical drugs octreotide and paltusotine. Nat Commun 2023;14(1):962. doi:10.1038/s41467-023-36673-z
41. Yamamoto M, Takahashi Y. Genetic and epigenetic pathogenesis of acromegaly. Cancers (Basel) 2022;14(16):3861. doi:10.3390/cancers14163861
42. Bopp MH, Saß B, Pojskić M, Corr F, Grimm D, Kemmling A, et al. Use of neuronavigation and augmented reality in transsphenoidal pituitary adenoma surgery. J Clin Med 2022;11(19):5590. doi:10.3390/jcm11195590
43. Maia B, Kasuki L, Gadelha MR. Novel therapies for acromegaly. Endocr Connect 2020;9(12): R274-85. doi:10.1530/ec-20-0433
44. Buchfelder M, Schlaffer SM. Novel techniques in the surgical treatment of acromegaly: applications and efficacy. Neuroendocrinology 2016;103(1):32-41. doi:10.1159/000441980
45. Buchfelder M, Schlaffer SM, Zhao Y. The optimal surgical techniques for pituitary tumors. Best Pract Res Clin Endocrinol Metab 2019;33(2):101299. doi:10.1016/j.beem.2019.101299
46. Sousa BR, Parreira RC, Fonseca EA, Amaya MJ, Tonelli FM, Lacerda SM, et al. Human adult stem cells from diverse origins: an overview from multiparametric immunophenotyping to clinical applications. Cytometry A 2014;85(1):43-77. doi:10.1002/cyto.a.22402
47. Neggers S, Badiu C, Biagetti B, Durand-Gasselin L, Petit A, Petrossians P, et al. Pharmacological and safety profile of a prolonged-release lanreotide formulation in acromegaly. Expert Rev Clin Pharmacol 2021;14(12):1551-60. doi:10.1080/17512433.2021.1986004
48. Gadelha MR, Wildemberg LE, Kasuki L. The future of somatostatin receptor ligands in acromegaly. J Clin Endocrinol Metab 2022;107(2):297-308. doi:10.1210/clinem/dgab726
49. Giustina A, Barkhoudarian G, Beckers A, Ben-Shlomo A, Biermasz N, Biller B, et al. Multidisciplinary management of acromegaly: a consensus. Rev Endocr Metab Disord 2020;21(4):667-78. doi:10.1007/s11154-020-09588-z
50. Chiloiro S, Bima C, Tartaglione T, Giampietro A, Gessi M, Lauretti L, et al. Pasireotide and pegvisomant combination treatment in acromegaly resistant to second-line therapies: a longitudinal study. J Clin Endocrinol Metab 2019;104(11):5478-82. doi:10.1210/jc.2019-00825
51. Labadzhyan A, Melmed S. Molecular targets in acromegaly. Front Endocrinol (Lausanne) 2022;13:1068061. doi:10.3389/fendo.2022.1068061
52. Henriques DG, Miranda RL, Dezonne RS, Wildemberg LE, da Silva Camacho AH, Chimelli L, et al. miR-383-5p, miR-181a-5p, and miR-181b-5p as predictors of response to first-generation somatostatin receptor ligands in acromegaly. Int J Mol Sci 2023;24(3):2875. doi:10.3390/ijms24032875
53. Wildemberg LE, Neto LV, Costa DF, Nasciuti LE, Takiya CM, Alves LM, et al. Low somatostatin receptor subtype 2, but not dopamine receptor subtype 2 expression predicts the lack of biochemical response of somatotropinomas to treatment with somatostatin analogs. J Endocrinol Invest 2013;36(1):38-43. doi:10.3275/8305
54. Fan X, Mao Z, He D, Liao C, Jiang X, Lei N, et al. Expression of somatostatin receptor subtype 2 in growth hormone-secreting pituitary adenoma and the regulation of miR-185. J Endocrinol Invest 2015;38(10):1117-28. doi:10.1007/s40618-015-0306-7
55. Melmed S, Bronstein MD, Chanson P, Klibanski A, Casanueva FF, Wass JA, et al. A consensus statement on acromegaly therapeutic outcomes. Nat Rev Endocrinol 2018;14(9):552-61. doi:10.1038/s41574-018-0058-5
56. Syro LV, Rotondo F, Serna CA, Ortiz LD, Kovacs K. Pathology of GH-producing pituitary adenomas and GH cell hyperplasia of the pituitary. Pituitary 2017;20(1):84-92. doi:10.1007/s11102-016-0748-8
57. Raverot G, Burman P, McCormack A, Heaney A, Petersenn S, Popovic V, et al. European Society of Endocrinology Clinical Practice Guidelines for the management of aggressive pituitary tumours and carcinomas. Eur J Endocrinol 2018;178(1): G1-24. doi:10.1530/eje-17-0796
58. Liu W, Fleseriu M. Individualized acromegaly treatment: is stereotactic radiation therapy changing the paradigm? Front Endocrinol (Lausanne) 2022;13:1034576. doi:10.3389/fendo.2022.1034576
59. Najafipour F, Jafarpour J, Bahrami A, Mobasseri M, Niafar M, Najafipour M, et al. The long-term effects of postoperative radiotherapy in acromegaly: results from a single-center acromegaly registry in Iran. Int J Endocrinol 2025;2025:9945510. doi:10.1155/ije/9945510
60. Zhang HR, Li JK, Yang XG, Qiao RQ, Hu YC. Conventional radiotherapy and stereotactic radiosurgery in the management of metastatic spine disease. Technol Cancer Res Treat 2020;19:1533033820945798. doi:10.1177/1533033820945798
61. Balossier A, Tuleasca C, Cortet-Rudelli C, Soto-Ares G, Levivier M, Assaker R, et al. Gamma Knife radiosurgery for acromegaly: evaluating the role of the biological effective dose associated with endocrine remission in a series of 42 consecutive cases. Clin Endocrinol (Oxf) 2021;94(3):424-33. doi:10.1111/cen.14346
62. Uygur MM, Deyneli O, Yavuz DG. Long-term endocrinological outcomes of gamma knife radiosurgery in acromegaly patients. Growth Horm IGF Res 2020;55:101335. doi:10.1016/j.ghir.2020.101335
63. Romero-Gameros CA, González-Virla B, Vargas-Ortega G, Sosa-Eroza E, Rendón-Macías ME, Balcázar-Hernández LJ, et al. Efficiency and safety of CyberKnife robotic radiosurgery in the multimodal management of patients with acromegaly. Cancers (Basel) 2023;15(5):1438. doi:10.3390/cancers15051438
64. Iwata H, Sato K, Nomura R, Tabei Y, Suzuki I, Yokota N, et al. Long-term results of hypofractionated stereotactic radiotherapy with CyberKnife for growth hormone-secreting pituitary adenoma: evaluation by the Cortina consensus. J Neurooncol 2016;128(2):267-75. doi:10.1007/s11060-016-2105-1

65. Gheorghiu ML. Updates in outcomes of stereotactic radiation therapy in acromegaly. Pituitary 2017;20(1):154-68. doi:10.1007/s11102-016-0783-5
66. Sahakian N, Castinetti F, Brue T, Cuny T. Current and emerging medical therapies in pituitary tumors. J Clin Med 2022;11(4):955. doi:10.3390/jcm11040955
67. Zhao J, Wang S, Markison S, Kim SH, Han S, Chen M, et al. Discovery of paltusotine (CRN00808), a potent, selective, and orally bioavailable non-peptide SST2 agonist. ACS Med Chem Lett 2023;14(1):66-74. doi:10.1021/acsmedchemlett.2c00431
68. Puig-Domingo M, Bernabéu I, Picó A, Biagetti B, Gil J, Alvarez-Escolá C, et al. Pasireotide in the personalized treatment of acromegaly. Front Endocrinol (Lausanne) 2021;12:648411. doi:10.3389/fendo.2021.648411